



DUAL INNERVATION OF GLUTEUS MAXIMUS MUSCLE BY POSTERIOR FEMORAL CUTANEOUS NERVE AND INFERIOR GLUTEAL NERVE: A CASE REPORT

Vrinda Hari Ankolekar¹, Antony Sylvan Dsouza² & Mamatha Hosapatna*¹

¹Assistant professor, ²Professor and Head, Department of Anatomy, Kasturba Medical College, Manipal.

*Corresponding Author Email: mamatha2010@yahoo.com

ABSTRACT:

The posterior femoral cutaneous nerve is a nerve from the sacral plexus. It arises partly from the dorsal divisions of the first and second, and from the ventral divisions of the second and third sacral nerves. Its branches are all cutaneous, and are distributed to the gluteal region, the perineum, and the back of the thigh and leg. In the present case we observed unusual muscular branches from the posterior femoral cutaneous nerve innervating the gluteus maximus which is not mentioned in the literature earlier.

KEYWORDS:

Sacral plexus, posterior femoral cutaneous nerve, gluteus maximus, inferior gluteal nerve

INTRODUCTION

The gluteus maximus (GM) is the largest and the most superficial gluteal muscle. It makes up a large portion of the buttocks arising from the posterior gluteal line of ilium, outer sloping surface of the iliac crest, posterior surface of the lower part of the sacrum, the side of the coccyx. The fibers are directed obliquely downward and laterally. The larger upper and superficial portion of the muscle is inserted to the iliotibial tract and fascia lata. The lower deeper portion ends in a thick tendinous lamina and inserted to the gluteal tuberosity¹.

Gluteus maximus is supplied solely by the inferior gluteal nerve which is formed by the dorsal branches of the ventral rami of the fifth lumbar, first and second sacral nerves. It leaves the pelvis through the greater sciatic foramen, below the piriformis and divides into branches which enter the deep surface of gluteus maximus. It is responsible for the movement of GM in activities requiring the hip to extend the thigh.

The PFCN is a nerve from the sacral plexus. It arises partly from the dorsal divisions of the first and second, and from the ventral divisions of the second and third

sacral nerves. The PFCN leaves the pelvis emerging from the greater sciatic foramen beneath the piriformis muscle in a majority of cases. It then descends beneath the gluteus maximus and runs down the back of the thigh beneath the fascia lata, and over the long head of the biceps femoris to the back of the knee; here it pierces the deep fascia. Its branches are all cutaneous, and are distributed to the gluteal region, the perineum, and the back of the thigh and leg².

Irritation of the posterior femoral cutaneous nerve usually happens at the muscles of the lower part of the buttock. This is a very common injury in cyclists. Also, a direct fall onto a hard object also cause a crush injury to the Posterior Femoral Cutaneous Nerve³.

However, to the best of our knowledge, no cases, to date, have reported the posterior femoral cutaneous nerve innervating the gluteus maximus.

CASE REPORT

During regular dissections for undergraduate medical students, we observed a rare variation in the distribution of posterior femoral cutaneous nerve on the right side.

Mamatha Hosapatna* *et al*; DUAL INNERVATION OF GLUTEUS MAXIMUS MUSCLE BY POSTERIOR.....

The origin and course of posterior femoral cutaneous nerve was normal. It innervated the gluteus maximus muscle, which usually receives its nerve supply from inferior gluteal nerve. As usual it also gave cutaneous

branches to the perineal region, gluteal region and to the back of the thigh. The origin of inferior gluteal nerve was normal and it also supplied the gluteus maximus muscle as shown in Figure 1.

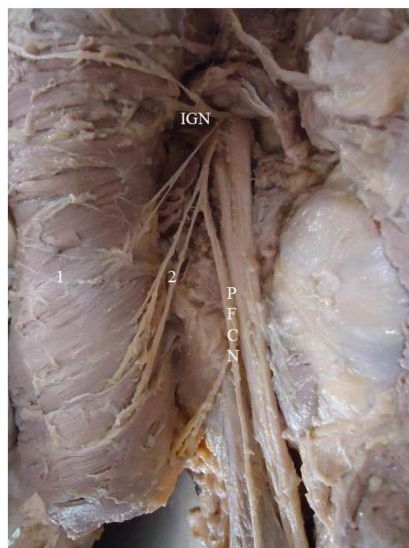


Figure 1 showing the following
IGN- Inferior gluteal nerve
PFCN- Posterior femoral cutaneous nerve
1. Gluteus maximus(GM)
2. Muscular branches to GM from PFCN

DISCUSSION

The posterior femoral cutaneous nerve (PFCN) consists exclusively of cutaneous nerve fibers and may exist from one to three nerves. Additional neural contributions have been documented as high as the fourth lumbar level to as low as the fourth sacral level¹.

Previous studies relating to the PFCN have focused mainly on its origin from the sacral plexus or its relationship to the piriformis muscle⁴. Other studies of PFCN include its contribution to the formation of sural nerve⁵, mononeuropathy related to a gluteal intramuscular injection posterior thigh pain immediately after uterosacral ligament fixation (USLF), landmarks of its perineal branch^{6,7}. There are many studies on the origin and distribution of the PFCN, several case reports on the PFCN neuropathy⁸, a nerve conduction study, and a free inferior gluteal flap study with sparing of the PFCN⁹.

However, to the best of our knowledge, no cases, to date, have reported the posterior femoral cutaneous nerve innervating the gluteus maximus.

The PFCN lies close to the sciatic nerve, and it is clear that injury to the PFCN by direct trauma cause damage to the larger sciatic nerve nearby. As a result, there have been very few reports of isolated PFCN neuropathy.

Since 1968, only nine cases studies have been reported. Isolated PFCN neuropathy is known to occur in situations that promote compression of this nerve, such as hematoma or tumor formation in the presacral regions, prolonged bicycling, and falls on the buttock. PFCN neuropathy can also result from direct injury secondary to intragluteal injection⁶. If this occurs, the loss of sensation in the posterior thigh is seen, and sensory loss in the inferior medial buttock region that is consistent with an inferior medial clunial nerve lesion may be added. This is explained by the fact that as the PFCN leaves the sciatic foramen, it gives rise to inferior medial clunial branches that provide sensory innervation to the inferior posterior buttock⁷.

PFCN is vulnerable to damage during uterosacral ligament fixation. Flynn MK et al. postulated that the nerve likely to be damaged in uterosacral ligament fixation if the sutures were placed too far laterally. So if posterior cutaneous is giving muscular branches to GM then there may be a slight weakness of GM¹⁰.

CONCLUSION

The PFCN has been widely investigated regarding its origin, distribution and mononeuropathies. However, its

Mamatha Hosapatna* et al; DUAL INNERVATION OF GLUTEUS MAXIMUS MUSCLE BY POSTERIOR.....

distribution to Gluteus maximus muscle is a rare variation.

REFERENCES

1. Standing S, Mahadevan V, Collins P, Healy JC, Lee J, Niranjana NS, eds. Gray's Anatomy, The Anatomical Basis of Clinical Practice. 40th Ed., Spain, Philadelphia, Churchill Livingstone Elsevier. 2008; 1368–1371.
2. Hollinshead WH. Functional Anatomy of the Limbs and Back, fourth edition. Press of W.B. Saunders Company, pp:281-9, 1976.
3. Franklin C Wagner. Compression of the lumbosacral plexus and the sciatic nerve. In: Rober M Szabo, Nerve Compression Syndromes: Diagnosis and Treatments. Thorofare, U.S.A., pp: 267, 1989.
4. Nakanishi T, Kanno Y, Kaneshige, Comparative morphological remarks on the origin of the posterior femoral cutaneous nerve, AnatAnz, 1976, 139(1-2):8-23.
5. Uluotku H, Can MA, Kurtoglu Z, Formation and location of the sural nerve in the newborn, SurgRadiolAnat, 2000,22(2):97-100.
6. Kim JE, Kang JH, Choi JC, Lee JS, Kang SY, Isolated posterior femoral cutaneous neuropathy following intragluteal injection, Muscle Nerve, 2009, 40(5):864-866.
7. Tong HC, Haig A, Posterior femoral cutaneous nerve mononeuropathy: a case report, Arch Phys Med Rehabil, 2000,81(8):1117-1118.
8. S. Tunali, Neslihan Cankara, S. Albay. A rare case communicating branch between the posterior femoral cutaneous and the sciatic nerves. Rom J Morphol Embryol 2011, 52(1):203-205
9. Collins SA, Downie SA, Olson TR, Mikhail MS, Nerve injury during uterosacral ligament fixation: a cadaver study, IntUrogynecol J Pelvic Floor Dysfunct, 2009, 20(5):505-508.
10. Flynn MK, Weidner AC, Amundsen CL, Sensory nerve injury after uterosacral ligament suspension, Am J ObstetGynecol, 2006, 195(6):1869-1872.



*Corresponding author Email address:
mamatha2010@yahoo.com