

A CASE REPORT OF MULTIPLE ADENOMATOUS POLYPS OF THE STOMACH AND COLON

Vidhya Subramanian, Hemalatha, B.O.Parijatham.

*Department of Pathology, Sree Balaji Medical College and Hospital
No. 7, Works Road, Chromepet, Chennai - 600 044.*

*Corresponding Author Email: onsivvidhya@yahoo.com

ABSTRACT:

Familial Adenomatous Polyposis is a syndrome contains more than 100 adenomatous polyps in large intestine ⁽¹⁾ It is associated with mutation of APC gene located on chromosome 5q21 or mutation of base excision repair gene MYH.1, It is a pre-malignant condition usually develop in late teens to early twenties ^(2,3) This case is presented here for rarity of age and clinical presentation. A 60 years female diagnosed with multiple adenomatous polyps in stomach and malignant transformation with few adenomatous polyps in large intestine. The family screening confirmed her son as well had colonic polyps.

KEYWORDS:

Multiple adenomatous Polyps, stomach.

INTRODUCTION

Familial polyposis syndrome are rare autosomal dominant syndrome with 100% chance of malignant progression ⁽⁴⁾ Gastric polyps can occur in 30-100% of cases of FAP (aka. FGP). Gastric adenomatous polyps and fundic gland polyps occurs in only 5% of FAP ^(5,6). Prevalence of FAP 1/5000 to 7500 ^(7,8).

CLINICAL HISTORY

60 year female came with complains of abdominal pain and nausea for 2 weeks, No history of vomiting, fever,

loose stools and altered bowel habits. Investigation done, Peripheral smear revealed Microcytic Hypochromic anaemia, USG abdomen was normal, stool for occult blood was negative, OGD Scopy revealed two pedunculated polyps in fundus of stomach and multiple sessile polyps in body of stomach (Fig.1), Colonoscopy revealed Multiple sessile polyps seen in Sigmoid, Ascending, Transverse and Descending colon(Fig. 2), Chest/Skull/Pelvis X-rays were normal, CT Brain was normal study.

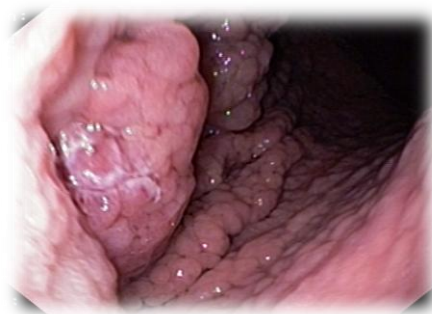

Fig 1: OGD Scopy showing Pedunculated and Sessile polyps in fundus of stomach.

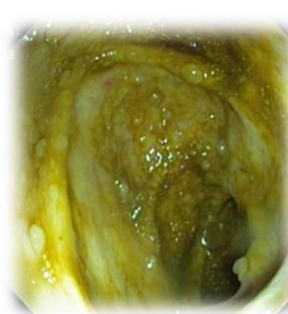


Fig 2: Colonoscopy showing multiple polyps

GROSSING

Total gastrectomy specimen measured 30×13×8 cm, numerous sessile polyps ranging from less than 0.2 cm to 1.2 cm in diameter were noted and one polypoidal mass

measured 8×4 cm present in funds of stomach, one focus of puckering in the serosa was seen.(Fig.3) Colonic polyp measured 1.5×1 cm AE.

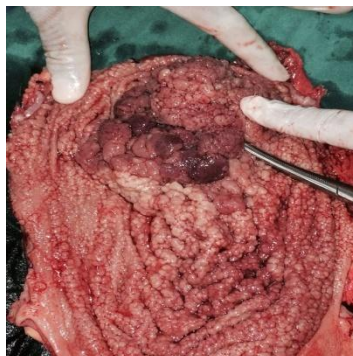

Fig 3: Gastrectomy specimen shows multiple polyps.

MICROSCOPY

Section from the gastrectomy specimen showed a polypoidal mass, composed of distorted and crowded glands with increased stratification of lining epithelium, crowding of nuclei, arranged in a papillary and glandular pattern infiltrated the muscle layer up to the serosa,

showed areas of necrosis and multiple polypoidal lesion composed of tubular glands, cystically dilated glands with dysplastic epithelium (Fig. 4,5,6 & 7), Colonic polyps composed of tubular glands, cystically dilated glands and showed dysplastic changes.

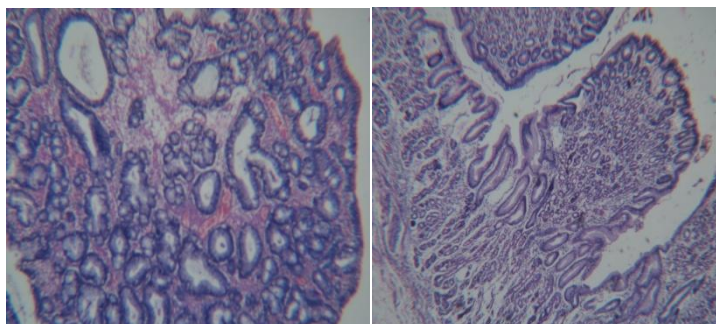


Fig 4 and 5: H & E, 100x, Adenomatous polyps of stomach.

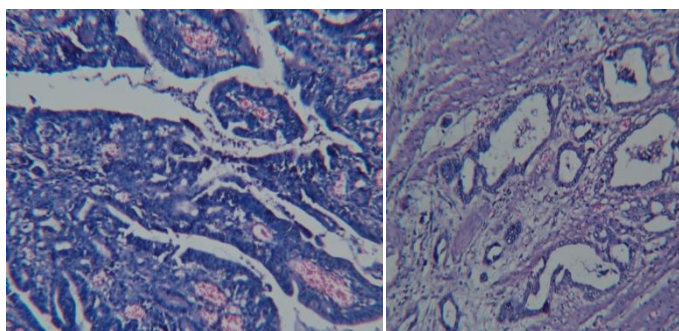


Fig 6 and 7: H & E, 100x, Transformed Neoplastic cells infiltration to muscular layer of stomach.

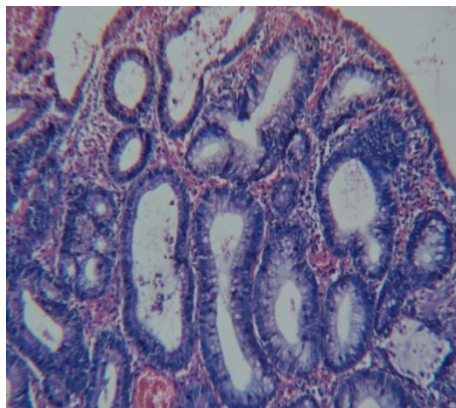


Fig 8: H& E, 100x, Few adenomatous polyps of colon.

DISCUSSION

Clinical description of polyps of large intestine was defined by Menzelio. Cripps reported FAP findings⁽⁹⁾. The genetic findings of FAP was described by Lockhart⁽¹⁰⁾. Mummery explained that the malignant potential of adenomatous polyps. Gardner described the syndrome which has polyps along with extra colonic manifestation like osteomas and soft tissue tumor. The location of APC gene at 5q21 was confirmed by Bodmer et al. APC gene is a tumor suppressor gene. Mutation of APC gene causes proliferation of mucosa of gastrointestinal tract and polyposis⁽¹¹⁾. Attenuated FAP is a autosomal recessive condition characterized by fewer than 100 adenomas and it is caused by mutation of MutY homologue (MYH) gene. Risk of developing gastrointestinal cancer is high for the patient with FAP so early regular gastrointestinal screening is essential in patient with FAP⁽¹²⁾. Adenomas are common in older patients with FAP and prone for adenocarcinoma⁽¹³⁾. Fundic gland polyps are common with familial adenomatous polyposis but pathogenesis of FGPs in FAP and spodic patients are not clear. Rarely invasive gastric adenocarcinoma also reported in patient with FAP and fundic gland polyposis. FGPs in FAP patients are pathogenetically distinct from sporadic FGPs. Somatic, second-hit APC gene alterations causes morphological changes in FAP-associated FGPs, indicate that FGPs arising in the setting of FAP are neoplastic lesions⁽¹⁴⁾. Patient with classic FAP are advised for genetic testing, family members are advised

undergo annual sigmoidoscopy or colonoscopy until colectomy is deemed by physician, Patients undergone colectomy and retained recutum should undergo flexible sigmoidoscopy every 6 to 12 months. If patient's genetic testing is negative, has to undergo genetic testing for MYH mutation, Patient with less than 100 adenomas should undergo genetic testing for attenuated FAP and if negative, MYH-associated polyposis.

This case report is unique because the patient presented with compliance of abdomen pain at the age of 60. And, had few colonic polyps and more polyps in stomach with malignant transformation, revealed by histopathological examination, colonoscopy and endoscopy respectively. Family screening done and found her son also had colonic polyps. So, patient and her family people are advised to go for genetic counseling and further treatment as necessary.

CONCLUSION

Polyps in the gastrointestinal tract may vary from asymptomatic benign harmless lesions to invasive malignancies. Various investigatory modalities are available in for screening and diagnosis of these lesions. The morphology of the polyps are well defined to delineate them from one another. A careful study of adenomatous polyps is needed in view of potential for malignant transformation, FAP due to APC or MYH gene mutation, therapeutic decision should be based on histo-pathological findings and patient's morbid

condition, Screening, follow-up, prophylactic colectomy will prevent the adenocarcinoma development. Constant education and awareness among patient with FAP about family screening and prevention of disease progression needed for better prevention or timely action.

REFERENCES

1. J. Tomsulo MD, " Gastric polyp: Histologic types and their relationship to gastric carcinoma" published online 27 June 2006, cancer, volume 27, issue 6, pg 1346-1353, June 1971.
2. M.Stolle et al., "Frequency, location, age and sex distribution of various types of gastric polyp" 1994; 26(8) 659-665, DOI- 10.1055/s. 2007-100906, 17 March 2008 (Online).
3. G.Ginsberg et al., " Gastric polyps: Relationship of size and histology to cancer risk." The American Journal of Gastroenterology, (1996,91 (4). 714-717) PMID: 8677935.
4. T.Nakamura et al., "Malignant changes in gastric polyps." Journal of clinical pathology, volume 38, issue 7, 1985, 38: 754-764, DOI 10-1136/JCP. 38.7.754.
5. AF. Ansher et al., "Hyperplastic colonic polyps as a marker for adenomatous colonic polyps" The American journal of Gastroenterology, (1989,84(2) 113-117) Europe Pub Med central, PMID: 2916517.
6. Hopital Charles Nicolle de Tunis et al, Histopathological study of gastric polyps, 2006 Oct; 84 (10) Tunis Med.
7. D. Beech et al., Familial adenomatous polyposis: a case report and review of the literature, Jun 2001; 93(6), J Natl Med Assoc.
8. Urbanski et al., " Hyperplastic adenomatous polyps-An underdiagnosed entity: Report of a case a mixed hyperplastic adenomatous polyp." American journal of surgical pathology, July 1984, volume 8, issue 7.
9. Avinash Bardia et al., FAP associated APC gene mutation - case study, J Med Allied Sci 2013; 3 (2) : 81-84, Indi.6, June 2001.
10. RG. Sarre et al. Gastric and duodenal polyps in familial adenomatous polyposis: a prospective study of the nature and prevalence of upper gastrointestinal polyps. Gut 1987;28:306-314 doi:10.1136/gut.28.3.306.
11. DG Jagelman et al. Upper gastrointestinal cancer in familial adenomatous polyposis, The Lancet, 331 volume, 8595 issue, pg 1149-1151, Elsevier Publisher
12. Susan et al. Fundic gland polyps in FAP: Neoplasms with frequent somatic adenomatous polyposis coli gene alteration, The American journal of pathology volume 157, issue 3, September 2000, pg 747-754.



***Corresponding author address:**

Email address:

onsivvidhya@yahoo.com